

AMI ECG, ANATOMY AND PATHOLOGY

LCX LESIONS ±

POSTERIOR MI

STE: V7-9
 STD: V1-2 (reciprocal STE)
 R:S ≥ 1: V1-2
 Tall T: V1-2
 RCA and LCX occlusion

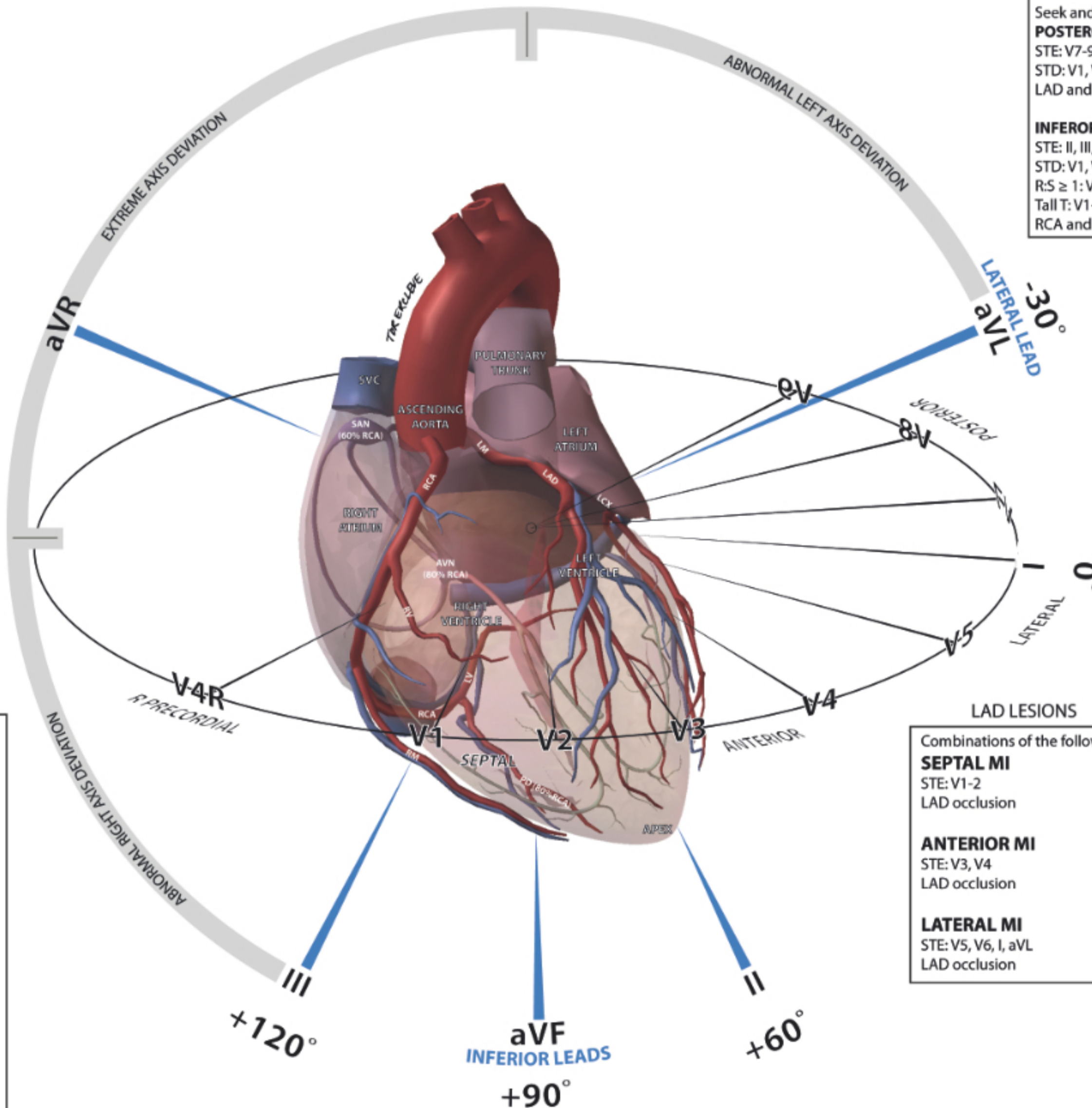
Seek and exclude

POSTEROLATERAL MI

STE: V7-9 and I, aVL, V5-6
 STD: V1, V2
 LAD and LCX occlusion

INFEROPOSTERIOR MI

STE: II, III, AVF and V7-9
 STD: V1, V2 (reciprocal STE)
 R:S ≥ 1: V1-2
 Tall T: V1-2
 RCA and LCX occlusion



RCA 'TYPE' LESIONS ±

INFERIOR MI

STE: II, III, aVF
 STD: aVL (reciprocal STE)
 RCA occlusion distal to RV
 58% of MI

Seek and exclude

INFERIOR AND RV MI

STE: II, III, aVF and V1, V4R
 RCA occlusion proximal to RV
 40% of Inferior MI
 Increased mortality risk

INFEROLATERAL MI

STE: II, III, AVF and I, aVL, V5, V6 ± V4R
 LAD and LCX occlusion
 in a L dominant system

INFEROPOSTERIOR MI

STE: II, III, AVF and V7-9
 STD: V1, V2 (reciprocal STE)
 R:S ≥ 1: V1-2
 Tall T: V1-2
 RCA and LCX occlusion

LAD LESIONS

Combinations of the following

SEPTAL MI

STE: V1-2
 LAD occlusion

ANTERIOR MI

STE: V3, V4
 LAD occlusion

LATERAL MI

STE: V5, V6, I, aVL
 LAD occlusion